

PubMed

Format: Abstract

Full text links

Ann Pediatr Cardiol. 2013 Jan;6(1):99-100. doi: 10.4103/0974-2069.107249.



Staged pacemaker implantation in a preterm with hydrops fetalis due to complete heart block.

Karande T¹, Garekar S, Kulkarni S, Rao S.

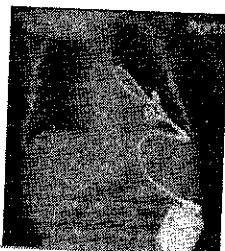
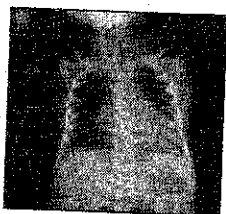
Author information

PMID: 23626451 PMCID: [PMC3634263](#) DOI: [10.4103/0974-2069.107249](#)

[Free PMC Article](#)

Images from this publication. [See all images](#)

(3) [Free text](#)



[LinkOut - more resources](#)

[PubMed Commons](#)

0 comments

[PubMed Commons home](#)

[How to join PubMed Commons](#)