

Native aortic coarctation in neonates and infants: Immediate and midterm outcomes with balloon angioplasty and surgery

Supratim Sen, Sandeep Garg¹, Suresh G Rao¹, Snehal Kulkarni¹

Department of Pediatric Cardiology, SRCC Children's Hospital, ¹Children's Heart Centre, Kokilaben Dhirubhai Ambani Hospital, Mumbai, Maharashtra, India

ABSTRACT

- Background** : Native aortic coarctation in young infants can be treated surgically or with balloon angioplasty, although the latter approach remains controversial. We sought to compare midterm outcomes of balloon and surgical coarctoplasty at our center and to review the current practices in literature.
- Methods** : The study design was a retrospective record review. Patients with coarctation aged <1 year who underwent balloon or surgical coarctoplasty at our center (January 2010–January 2016) with >6-month post-procedure follow-up were studied. Patients with significant arch hypoplasia or interruption, long-segment coarctation, and associated intracardiac lesions were excluded from the study. Clinical, echocardiographic, and procedural details were recorded at initial presentation and follow-up. Need for reintervention was noted.
- Results** : Out of a total of 75 patients, 28 underwent balloon (Group A) and 47 underwent surgical coarctoplasty (Group B). There were two deaths in Group B (mortality 4.2%) and none in Group A. In neonates, 63.6% of Group A and 17.4% of Group B patients required reintervention ($P = 0.007$). Beyond the neonatal age, 29.4% of Group A and 41.6% of Group B patients required reintervention (not statistically significant). On univariate analysis, residual coarctation on predischarge echocardiogram was the only significant predictor of reintervention ($P = 0.04$). On Kaplan–Meier analysis, with neonatal presentation, freedom from reintervention in Group B was significantly higher than Group A ($P = 0.028$).
- Conclusion** : In neonates with native aortic coarctation, surgery unequivocally yields better immediate and midterm results and is the preferred treatment modality. In older infants, balloon coarctoplasty has good early and midterm outcomes with acceptable reintervention rates and should be considered a viable alternative to surgery, especially in critical patients with high surgical risk.
- Keywords** : Balloon angioplasty, coarctation of the aorta, surgical coarctation repair

INTRODUCTION

Coarctation of the aorta accounts for approximately 6%–8% of congenital heart defects.^[1] Both surgical repair

and transcatheter angioplasty for coarctation are widely available and well-studied treatment strategies.^[1–4] In

Access this article online	
Quick Response Code: 	Website: www.annalspc.com
	DOI: 10.4103/apc.APC_165_17

This is an open access journal, and articles are distributed under the terms of the Creative Commons Attribution-NonCommercial-ShareAlike 4.0 License, which allows others to remix, tweak, and build upon the work non-commercially, as long as appropriate credit is given and the new creations are licensed under the identical terms.

For reprints contact: reprints@medknow.com

How to cite this article: Sen S, Garg S, Rao SG, Kulkarni S. Native aortic coarctation in neonates and infants: Immediate and midterm outcomes with balloon angioplasty and surgery. *Ann Pediatr Card* 2018;11:261-6.

Address for correspondence: Dr. Supratim Sen, Department of Pediatric Cardiology, SRCC Children's Hospital, 1-1A, Haji Ali Park, Mahalaxmi, Mumbai - 400 034, Maharashtra, India. E-mail: supratim80@gmail.com, Study conducted at: Kokilaben Dhirubhai Ambani Hospital, Mumbai, India.

Sen, *et al.*: Balloon angioplasty versus surgery in aortic coarctation

the current era, balloon angioplasty has become routine treatment for recoarctation and is widely accepted, along with stent implantation, as an alternative to surgical repair for native coarctation in older children and adults.^[5-7] However, the use of balloon angioplasty for native coarctation in neonates and infants remains controversial.^[2]

At our institution, the past practice for neonates and infants with discrete coarctation was to restrict balloon coarctoplasty to critically ill patients as a temporizing salvage measure, while preferring surgical repair for hemodynamically stable infants. However, encouraged by excellent immediate and good midterm results with balloon angioplasty, we have gradually expanded indications for balloon angioplasty to include most infants with isolated discrete aortic coarctation. We sought to compare midterm results of balloon angioplasty and surgical coarctation repair in our patients and review the current practices in world literature.

METHODS

The study design was a retrospective record review. We studied all patients with discrete coarctation of the aorta who underwent balloon coarctoplasty and surgical coarctation repair at our center between January 2010 and January 2016 with age <1 year at the time of initial procedure and at least 6-month postprocedure follow-up.

Patients with more than mild aortic arch hypoplasia, long-segment coarctation, aortic arch interruption, and associated intracardiac lesions requiring surgery were excluded from the study.

Details at initial presentation including age, weight, and clinical condition were noted from patient records. Variables such as coarctation gradient, diameter of the transverse arch, isthmus and descending aorta, and left ventricular (LV) function were obtained from the initial echocardiogram report. LV dysfunction was categorized as mild, moderate, or severe based on the ejection fraction measured by M-mode in parasternal short- and long-axis views on the baseline and follow-up echocardiograms. Ejection fraction of 45%–55% was categorized as mild, 30%–44% as moderate, and <30% as severe LV dysfunction.

Intervention for native or recurrent coarctation was performed if the upper-to-lower limb systolic pressure gradient was >20 mmHg, the peak systolic echocardiographic gradient was >40 mmHg, the mean echocardiographic gradient was >20 mmHg, there was diastolic tailing of Doppler flow across the coarctation segment, the upper extremity systolic blood pressure exceeded the 95th centile for height centile with narrowing and flow turbulence on echocardiography,

and/or if coarctation was seen along with LV dysfunction, irrespective of the measured pressure gradient.

Details regarding the balloon angioplasty procedure including the balloon size and the baseline and postdilation ascending and descending aortic pressures were noted. All patients received a single heparin bolus (100 U/kg) after vascular access. All catheter manipulation was done over a guidewire kept across the dilated coarctation segment during the procedure. Rapid right ventricular pacing was not done. The balloon diameter for angioplasty was chosen based on standard recommendations that the diameter of the balloon must not exceed the diameter of the descending thoracic aorta at the level of the diaphragm or three times the diameter of the coarctation segment.^[8]

For surgical repair, details of surgical technique and postprocedure hospital stay were noted.

Postprocedure, clinical, and predischarge echocardiographic details including any residual coarctation gradient, aortic aneurysm/dissection, and LV function were recorded. Similar variables were analyzed on subsequent follow-up after a minimum of 6 months, including the most recent follow-up. Details of any reintervention were noted.

On echocardiography, discrete coarctation was defined as length of the coarctation segment <5 mm. Mild transverse arch hypoplasia was defined as a transverse arch z-score of –1 to –3. Residual coarctation postprocedure was defined as immediate residual peak-to-peak systolic gradient >20 mmHg in the catheterization laboratory.^[6] Aneurysm was defined as diameter >50% more than the descending aortic diameter at the level of diaphragm or a discrete protrusion extending outside the aortic adventitial plane by >3 mm in the postangioplasty aortogram or on the postprocedure echocardiogram.

Statistical analysis including Chi-squared test, general linear model univariate analysis, and Kaplan–Meier survival analysis for freedom from reintervention was done using IBM SPSS Statistics software, version 24 (IBM, New York, United States).

RESULTS

In the study period, a total of 134 neonates and infants underwent treatment for native aortic coarctation at our center. After excluding patients who had surgery for long-segment coarctation, significant arch hypoplasia, interruption, or associated intracardiac lesions, we identified 75 patients (34 neonates) with discrete coarctation, of which 28 patients underwent balloon angioplasty (Group A) and 47 patients underwent surgical repair (Group B).

The baseline characteristics are mentioned in Table 1. There was no significant difference in the median age,

mean weight, and male:female ratio in the balloon and surgical groups (Chi-squared test $P = 0.87$). The mean z-score of the isthmus on initial echocardiography was -2.43 ± 1.47 in Group A and -3.87 ± 1.63 in Group B. Almost half of the patients in both groups had mild transverse arch hypoplasia (z-score -1 to -3), with no statistically significant difference in the two groups (Chi-squared test $P = 0.89$). At presentation, 32.1% of Group A patients and 10.6% of Group B patients had severe LV dysfunction. Four patients in Group A and one patient in Group B were in shock. Surgical approach was through median sternotomy in all.

Postprocedure details are mentioned in Table 2. Residual coarctation was reported in the pre-discharge echocardiogram more frequently in Group A (28.6% vs. 6.4% in Group B). There were no major vascular complications in any patient. In Group A, five patients (three neonates) had transient loss of arterial pulse in the lower limb used for access with impaired perfusion immediately postprocedure. All were started on intravenous heparin infusion for 24 h. Four of them had complete recovery of perfusion and pulse within a few hours, while one patient had recovery of normal perfusion with persistence of feeble right lower limb pulses.

Table 1: Baseline characteristics

Therapeutic modality	Balloon coarctoplasty (Group A) (n=28)	Surgical coarctation repair (Group B) (n=47)
Age (months), median (range)	1.3 (0.18-10)	1.2 (0-12)
Weight (kg), mean±SD	3.87±1.70	3.80±1.77
Sex - male:female	20:8	35:12
<i>P</i>		0.87
Presentation		
Shock	4	1
Tachypnea, no shock	24	46
LV dysfunction		
None	12	29
Mild	2	8
Moderate	5	5
Severe	9	5
Echocardiographic findings		
Isthmus z-score, mean±SD	-2.43±1.47	-3.87±1.63
Associated mild transverse arch hypoplasia (%)	13 (46.4)	22 (46.8)
<i>P</i>		0.89

LV: Left ventricular, SD: Standard deviation

Table 2: Postprocedure details

Therapeutic modality	Balloon coarctoplasty (Group A) (n=28)	Surgical coarctation repair (Group B) (n=47)
Coarctation gradient at discharge, median (range)	18 (6-60)	17 (0-37)
Significant residual coarctation on pre-discharge echo (%)	8 (28.6)	3 (6.4)
Hospital stay (days), median (range)	2 (1-20)	15 (10-44)
Follow up duration (months), median (range)	6 (6-68)	6 (6-42)
Reintervention (neonates) (%)	7 (63.6)	4 (17.4)
Reintervention (1-12 months) (%)	5 (29.4)	10 (41.6)
Interval to reintervention (months), mean±SD	3.1±2.2	4.5±1.9

SD: Standard deviation

The median duration of follow-up was similar in both groups [Table 2]. The surgical techniques used in Group B patients are specified in Table 3. None of our patients developed aneurysms in the immediate or midterm follow-up. There were two deaths (hospital mortality: 4.2%) in Group B and none in Group A. There was no further mortality on midterm follow-up. Reintervention was required in 12 (42.8%) Group A patients and 14 (29.8%) Group B patients. Among the Group A patients, eight underwent repeat balloon coarctoplasty and four underwent surgical repair. In the Group B patients, all 14 underwent balloon coarctoplasty.

There was a notable difference in the recovery of LV function following surgery versus balloon angioplasty. All Group B patients with severe LV dysfunction at presentation had complete recovery to normal function on follow-up. In Group A, among those with severe LV dysfunction initially, one patient had mild LV dysfunction, five patients had moderate LV dysfunction, and three patients had severe LV dysfunction on follow-up. Residual coarctation on pre-discharge echocardiogram was observed in two of the eight patients with persisting moderate or severe LV dysfunction. However, five of these eight patients eventually underwent reintervention for suboptimal relief of coarctation after a median of 39 months (range: 4-77 months).

For further analysis of risk factors for reintervention, patients were grouped into neonates (age 0-1 month) and nonneonates (age >1-12 months) at presentation. In neonates, 63.6% of in Group A and 17.4% in Group B patients required reintervention: balloon coarctoplasty was associated with a significantly higher reintervention rate (Chi-squared test $P = 0.007$). In infants aged 1 month to 1 year, 29.4% in Group A and 41.6% in Group B patients required reintervention (no statistically significant difference).

On univariate analysis, residual coarctation on the pre-discharge echocardiogram was found to be the only significant predictor of reintervention (general linear model univariate analysis of variance $P = 0.04$). On Kaplan-Meier survival analysis for reintervention with neonatal presentation, freedom from reintervention in Group B was significantly higher than Group A ($P = 0.028$). Freedom from reintervention was also greater for

Sen, *et al.*: Balloon angioplasty versus surgery in aortic coarctation

Group B as a whole and conversely greater for Group A than Group B for presentation between 1 and 12 months (not statistically significant) [Figures 1-3].

DISCUSSION

Surgical repair for aortic coarctation was introduced in the 1940s,^[1,2] and four decades later, transcatheter balloon angioplasty was described by Lock *et al.*^[3] In the present era, balloon coarctoplasty and stent implantation have gained acceptance over surgery in the treatment of older children and adults with discrete coarctation.^[2,5,7,9] In infants, while balloon angioplasty is widely accepted for postoperative recoarctation, it remains controversial in native coarctation.^[2,9,10] This dichotomy of treatment strategies for native versus recurrent coarctation in infants is due to a perception of suboptimal early results^[3] with an increased risk of aortic rupture, major vascular complications, and late aortic aneurysms following balloon angioplasty in native lesions.^[6,10] Dilation of recoarctation is considered safer because of the surrounding surgical scar tissue with a presumed reduced risk of aortic rupture. However, McCrindle *et al.* eloquently demonstrated equivalent acute results of balloon dilatation in native and recurrent coarctation and noted that acute aortic tears do not occur with

dilation of native coarctation.^[6] Hence, this distinction of treatment strategies for native and recurrent coarctation is not logically justified.

Effective balloon angioplasty for coarctation causes a controlled tear through the intima and part of the media but not involving the adventitia due to radial forces.^[8,11] However, following balloon angioplasty in neonates, the abnormal ductal tissue remains despite an immediate adequate controlled tear, and subsequent elastic recoil of ductal tissue at the coarctation site and intimal hyperplasia secondary to smooth muscle cell proliferation^[10] may predispose to recoarctation.

Thus, although recent studies of balloon angioplasty have reported good immediate procedural success and safety in infants with native coarctation, early recurrence rates are undoubtedly high compared to surgery.^[4] Incidence of a residual gradient >20 mmHg ranges from 8% to 27% in various studies.^[1] Francis *et al.* reported a 100% restenosis rate with reintervention after a median interval of 12 weeks in 10 infants who underwent ballooning or stenting of coarctation.^[9] Fiore *et al.* reported a reintervention rate of 83% for infants undergoing balloon coarctoplasty for native coarctation. Nearly 35% underwent repeat balloon dilation of which 37.5% (3 of 8) developed aneurysms.^[10] Similarly, at our center, we found a 64% reintervention rate following balloon dilation of coarctation in neonates. In a long-term randomized comparison of patients aged 3–10 years treated with balloon angioplasty and surgery, Cowley *et al.* noted similar immediate and long-term relief of coarctation in the two groups, albeit with significantly higher aneurysm formation in the balloon angioplasty group.^[12] About 35% (7 of 20) of balloon patients developed aneurysms, of which 2 had elective surgery and 5 were on conservative follow-up.^[12] Contrasting

Table 3: Technique used for surgical repair (Group B)

Surgical technique	Total	Number requiring reintervention (percentage of total)
Interposition graft	1	0
Pericardial patch coarctoplasty	23	10 (43.4)
Resection and end to end anastomosis	21	4 (19.0)
Subclavian flap coarctoplasty	2	0

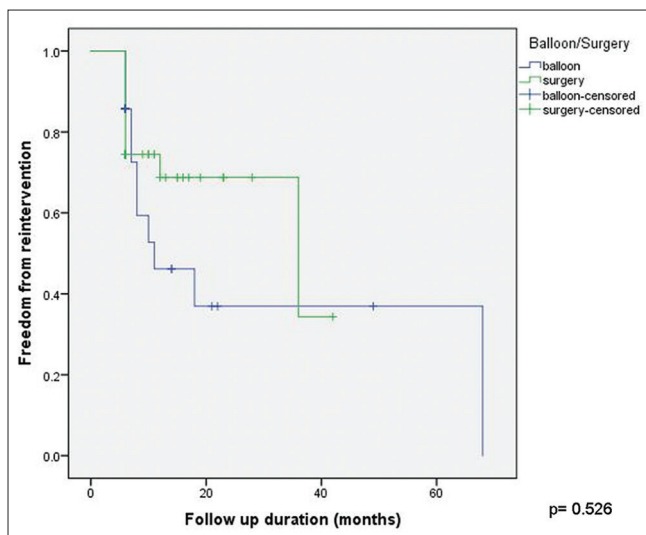


Figure 1: Freedom from reintervention for surgery and balloon coarctoplasty ($P = 0.526$, not significant)

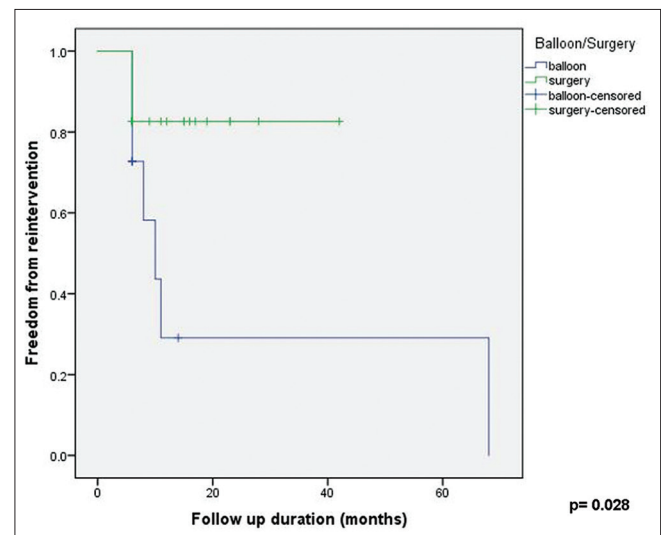


Figure 2: Freedom from reintervention for surgery and balloon coarctoplasty in neonates ($P = 0.028$, significant)

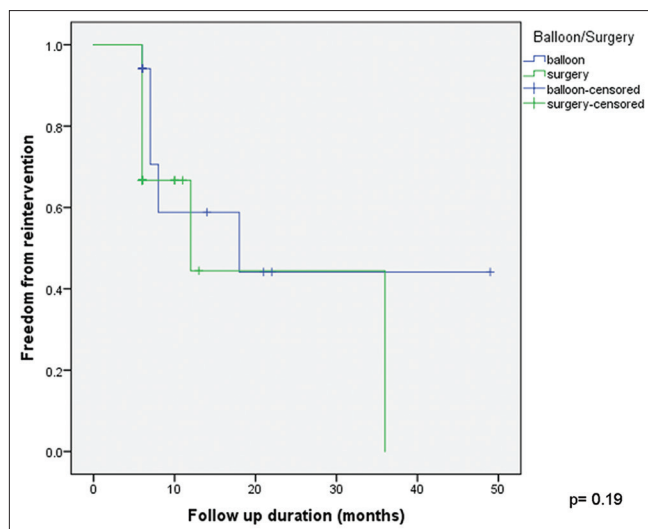


Figure 3: Freedom from reintervention for surgery and balloon coarctoplasty at 1–12-month age ($P = 0.19$, not significant)

results were described in another long-term review of balloon angioplasty and surgery in children aged 3 months to 16 years by Dijkema *et al.* Aneurysm rates were low and comparable in the balloon angioplasty and surgery groups (5% and 3%, respectively).^[13] However, significantly higher recoarctation rates (47% vs. 24%) were reported in the angioplasty patients in this study. Based on their contrasting data, the authors postulated that less aggressive balloon angioplasty at the time of the initial procedure may be associated with lower rates of aneurysm formation at the cost of higher recoarctation and reintervention rates.^[13]

However, surgical coarctation repair in a critically ill infant with native coarctation is not without hazards. Mortality rates have decreased from 10% in older studies^[1] to 0%–4.4% in recent series.^[14,15] Yet, paraparesis, vocal cord paresis,^[16] phrenic nerve palsy, diaphragmatic palsy, chylothorax, persistent hypertension,^[17] pneumothorax, necrotizing enterocolitis, wound infection, and dehiscence^[14] are all described complications following surgery. Recoarctation rates of 18%^[10] and aortic aneurysms in 9%–20% of patients^[8] have been reported following surgery in literature. The mean duration from surgery to aneurysm is reportedly >12 years^[8] and hence may be underreported in series analyzing immediate and midterm outcomes.

In our patient cohort, immediate results were good with no acute aortic rupture/dissection or death following balloon angioplasty. Residual coarctation on the predischarge echocardiogram was the only significant predictor of reintervention on univariate analysis. We did note a significantly higher reintervention rate following balloon angioplasty in neonates, and on Kaplan–Meier analysis, freedom from reintervention for surgical patients was significantly better in the neonatal

age group. However, in infants outside the neonatal age, balloon angioplasty actually had a higher freedom from reintervention although not statistically significant. Our surgical reintervention rate in older infants (42%) was higher than reported in literature and was most common following bovine pericardial patch arch augmentation. We have thus modified surgical strategies to decrease the use of glutaraldehyde-preserved bovine pericardial patches in arch repairs. In patients presenting with severe LV dysfunction, while balloon angioplasty was the preferred salvage procedure, we observed suboptimal recovery of LV function following balloon dilation compared to surgery. Hence, conservative balloon coarctoplasty in critically ill patients with severe LV dysfunction may not adequately relieve the obstruction, and while acceptable as an emergency intervention, will most likely require subsequent repeat angioplasty or surgery. Morbidity following surgery was more than with angioplasty, as evidenced by a longer length of hospital stay.

So is surgical repair always better in neonates and infants with native aortic coarctation? While most recent long-term studies do recommend surgery for neonates and infants with coarctation, we believe that there are three caveats to routinely choosing surgery over balloon angioplasty. First, the initial procedural morbidity and hospital stay are clearly more with arch surgery with a consequent higher cost of hospitalization as compared to a balloon dilation. This is more so for critically ill infants presenting with LV dysfunction and shock, where surgical risks are higher and postoperative recovery slower. This cost factor influences decision-making in developing countries with limited resources. Second, although reintervention rates following angioplasty are high, the reintervention of choice is often another transcatheter procedure such as a repeat balloon angioplasty or stenting, rather than future surgical repair. And finally, even in those patients where aneurysms are detected many years postangioplasty, the clinical significance is uncertain as patients are often kept on conservative follow-up and not routinely sent for surgical repair.

CONCLUSION

Based on our results and review, in neonates, surgery unequivocally yields better immediate and midterm results and should be considered the preferred treatment modality for native aortic coarctation. In infants outside the neonatal age, balloon coarctoplasty has good immediate and midterm outcomes with acceptable reintervention rates and should be considered a viable alternative to surgery, especially in critically ill patients with high surgical risk.

Study limitations

The retrospective design precluded randomization of patients into the balloon angioplasty and surgical

Sen, *et al.*: Balloon angioplasty versus surgery in aortic coarctation

groups. In addition, we have an institutional bias for preferring balloon dilation for critically ill patients with severe LV dysfunction or shock. As this is a single-center experience, the treatment strategies are uniform and may have skewed the patient distribution in the balloon and surgery groups. The duration of follow-up did not allow analysis of long-term outcomes. As our follow-up evaluation included a routine echocardiogram but no angiogram or computed tomography/magnetic resonance angiogram, small aneurysms may have been missed on echocardiography.

Financial support and sponsorship

Nil.

Conflicts of interest

There are no conflicts of interest.

REFERENCES

1. Beekman RH 3rd. Coarctation of the aorta. In: Allen HD, Driscoll DJ, Shaddy RE, Feltes TF, editors. Moss and Adams' Heart Disease in Infants, Children, and Adolescents. 7th ed. Philadelphia: Lippincott Williams & Wilkins; 2008. p. 987-1005.
2. Rao PS. Transcatheter interventions in critically ill neonates and infants with aortic coarctation. *Ann Pediatr Cardiol* 2009;2:116-9.
3. Lock JE, Bass JL, Amplatz K, Fuhrman BP, Castaneda-Zuniga W. Balloon dilation angioplasty of aortic coarctations in infants and children. *Circulation* 1983;68:109-16.
4. Vergales JE, Gangemi JJ, Rhueban KS, Lim DS. Coarctation of the aorta-the current state of surgical and transcatheter therapies. *Curr Cardiol Rev* 2013;9:211-9.
5. Kenny D, Hijazi ZM. Coarctation of the aorta: From fetal life to adulthood. *Cardiol J* 2011;18:487-95.
6. McCrindle BW, Jones TK, Morrow WR, Hagler DJ, Lloyd TR, Nouri S, *et al.* Acute results of balloon angioplasty of native coarctation versus recurrent aortic obstruction are equivalent. Valvuloplasty and angioplasty of congenital anomalies (VACA) registry investigators. *J Am Coll Cardiol* 1996;28:1810-7.
7. Warnes CA, Williams RG, Bashore TM, Child JS, Connolly HM, Dearani JA, *et al.* ACC/AHA 2008 guidelines for the management of adults with congenital heart disease: Executive summary: A report of the American College of Cardiology/American Heart Association Task Force on Practice Guidelines (writing committee to develop guidelines for the management of adults with congenital heart disease). *Circulation* 2008;118:2395-451.
8. Tretter JT, Jones TK, McElhinney DB. Aortic wall injury related to endovascular therapy for aortic coarctation. *Circ Cardiovasc Interv* 2015;8:e002840.
9. Francis E, Gayathri S, Vaidyanathan B, Kannan BR, Kumar RK. Emergency balloon dilation or stenting of critical coarctation of aorta in newborns and infants: An effective interim palliation. *Ann Pediatr Cardiol* 2009;2:111-5.
10. Fiore AC, Fischer LK, Schwartz T, Jureidini S, Balfour I, Carpenter D, *et al.* Comparison of angioplasty and surgery for neonatal aortic coarctation. *Ann Thorac Surg* 2005;80:1659-64.
11. Rao PS. Balloon angioplasty of aortic coarctation: A review. *Clin Cardiol* 1989;12:618-28.
12. Cowley CG, Orsmond GS, Feola P, McQuillan L, Shaddy RE. Long-term, randomized comparison of balloon angioplasty and surgery for native coarctation of the aorta in childhood. *Circulation* 2005;111:3453-6.
13. Dijkema EJ, Sieswerda GT, Takken T, Leiner T, Schoof PH, Haas F, *et al.* Long-term results of balloon angioplasty for native coarctation of the aorta in childhood in comparison with surgery. *Eur J Cardiothorac Surg* 2018;53:262-8.
14. Mery CM, Guzmán-Pruneda FA, Trost JG Jr., McLaughlin E, Smith BM, Parekh DR, *et al.* Contemporary results of aortic coarctation repair through left thoracotomy. *Ann Thorac Surg* 2015;100:1039-46.
15. Tulzer A, Mair R, Kreuzer M, Tulzer G. Outcome of aortic arch reconstruction in infants with coarctation: Importance of operative approach. *J Thorac Cardiovasc Surg* 2016;152:1506-130.
16. Shaddy RE, Boucek MM, Sturtevant JE, Ruttenberg HD, Jaffe RB, Tani LY, *et al.* Comparison of angioplasty and surgery for unoperated coarctation of the aorta. *Circulation* 1993;87:793-9.
17. Conte S, Lacour-Gayet F, Serraf A, Sousa-Uva M, Bruniaux J, Touchot A, *et al.* Surgical management of neonatal coarctation. *J Thorac Cardiovasc Surg* 1995;109:663-74.